

# OPTIMAL HEALTH UNIVERSITY™

Presented by Dr. Wayne Terai

## Little-Known Cause of Neck Pain May Be More Common Than Thought

*A late-breaking study led by a Danish chiropractor reveals that a little-known cause of neck pain may be more common than it was considered to be by the medical community. The condition, known as retropharyngeal tendinitis (RT), may be being under-recognized, or misdiagnosed.*

*Dr. Terai works diligently to remain abreast of current scientific studies, and to keep patients informed. Read on to learn about this fascinating new research.*

### What is RT?

The longus cervicis colli muscle assists with flexion and rotation of the neck. The muscle is attached to spinal bones (vertebrae) in the neck (cervical spine). The longus cervicis extends along the front sides of the spinal column in the space between the spine and the esophagus.

Retropharyngeal tendinitis (RT) involves a swelling of the longus cervicis colli muscle in the upper neck. Calcification of the muscle tendon where it inserts at the upper two spinal bones of the neck is also a characteristic. This calcification is due to hydroxyapatite crystal deposition. After the acute phase of the malady, calcification begins to resorb, with resorption usually complete by one to two weeks.

RT is known by many other names, including retropharyngeal calcific tendinitis (RCT) acute calcific retropharyngeal tendinitis, calcific prevertebral tendinitis, longus cervicis tendinitis, longus colli tendinitis, longus cervicis myositis.

### Symptoms

According to a just-published comprehensive study, the most common symptoms of RT are neck pain (94

percent), limited range of motion (45 percent), painful swallowing (45 percent), neck stiffness (42 percent), difficulty swallowing (27 percent), sore throat (17 percent) and neck spasm (11 percent). Low-grade fever is also common. In addition, blood tests may indicate slightly elevated white blood cells (leukocytosis) and erythrocyte sedimentation rate (*Semin Arthritis Rheum* 2009; Epub).

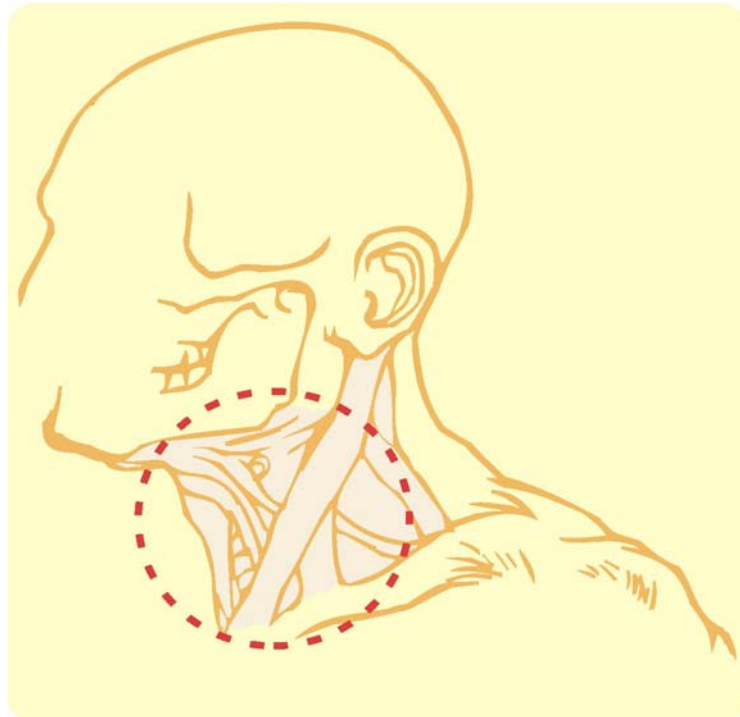
“Pain reaches a maximum at 2 to 5

days, then gradually subsides, usually completely by 1 to 2 weeks,” report researchers (*Am J Roentgenol* 1978;130:1137-40).

Although pain usually resolves within weeks, it is important to still schedule a visit with Dr. Terai because there may be hidden changes to the spine, which last after pain subsides.

### Link With Vertebral Subluxations

Patients with RT often suffer from a misalignment of the spinal bones of the neck — a condition known as **vertebral subluxation**. These dysfunctional areas affect not only the spine, but can also lead to problems throughout the body. Dr. Terai evaluates patient’s spines for vertebral subluxations, and prevents them with gentle and effective maneuvers known as **chiropractic adjustments**.



**Dr. Wayne Terai, Burtch Chiropractic (250) 860-4518  
229-1634 Harvey Avenue, Kelowna, BC V1Y 6G2 [www.burtchchiropractic.com](http://www.burtchchiropractic.com)**

## Chiropractic Study: RT May Be More Common Than Thought

Researchers in Denmark have discovered that retropharyngeal tendinitis is far more common among chiropractic patients than previously thought (*J Manipulative Physiol Ther* 2009;32:315-20).

“A practicing Danish chiropractor collected cases of retropharyngeal tendinitis from colleagues who were members of the Danish Society of Chiropractic and Clinical Biomechanics.”

Only cases where a patient history of acute severe neck pain, neck stiffness, and difficulty swallowing were considered, “and these were supplemented with imaging in the form of x-rays, computed tomography, or magnetic resonance imaging scans. All cases were reviewed independently by the chiropractor and a medical radiologist with a specialty in musculoskeletal disorders before acceptance into this case series.” (*J Manipulative Physiol Ther* 2009;32:315-20.)

“All but 2 patients had the characteristic depositions of calcium hydroxyapatite in the tendon of the longus colli muscle.”

The study concludes that “patients presenting with a triad of acute severe neck pain, stiff neck, and dysphagia [difficulty swallowing] may have retropharyngeal tendinitis. This condition may be more common than previously thought among patients presenting with acute neck pain in the primary health care sector.” (*J Manipulative Physiol Ther* 2009;32:315.)

## Under-Recognized

Researchers speculate that RT may often be misdiagnosed by medical doctors as whiplash, or another disorder.

One study explains that RT is distin-

guished by five salient features: “(1) The curious location of pain, mainly in the side of the neck. This is quite different from that experienced in common neck sprains of whiplash injury, which are maximal in the posterior neck muscles with radiation to the shoulders, occiput, and interscapular regions. (2) Pain aggravated by movement... (3) Pain is dramatically increased by swallowing. (4) Painful dysphagia is felt not in the throat, but in the side of the neck. Patients may be obliged to hold their necks to allow swallowing. (5) The illness is unaccompanied by fever or systemic disturbance and is self-limiting.” (*J Neurol Neurosurg Psychiatry* 1996; 61:324.)

## Typical Case

A research article published in the *Journal of Neurology, Neurosurgery and Psychiatry* describes a typical case of RT:

“A 42 year old secretary in excellent health fell, in the sitting position, into a stream. She had minor abrasions of the limbs but did not hurt her neck or head. Ten days later she developed a stiff neck. Turning the neck to the left side was painful, making driving difficult. After two days pain increased; prescribed methocarbamol failed to provide relief. On day 3 she had painful difficulty in swallowing, not in the throat but in the right side of the neck ‘as if the muscles and ligaments were strained,’ and painful movement was relieved when flexing her neck.” (*J Neurol Neurosurg Psychiatry* 1996; 61:324.)

“She consulted a neurophysiologists who found no neurological abnormality apart from painful restriction of rotation and lateral flexion, with no visible abnormality in the throat and no extremal bruision, swelling, or lymphadenopathy ...”

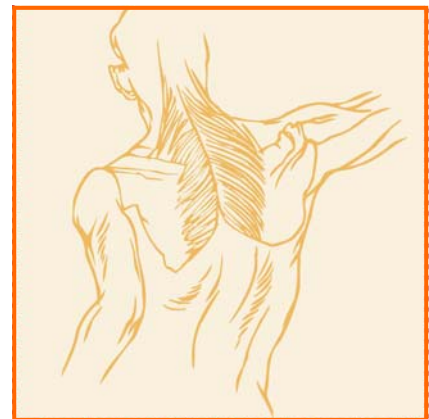
“Dysphagia [difficulty swallowing] increased until she could swallow only

small sips of water. She held her neck to ease swallowing. She also took to holding her head with both hands to enable her to lay her head on the pillow, and to sit up when getting out of bed. Sleeping in a soft collar provided slight relief ...” Her symptoms gradually improved, and had resolved by day 12 (*J Neurol Neurosurg Psychiatry* 1996;61:324).

## Don't Assume

If you suffer from symptoms of RT, it is vital to schedule a chiropractic checkup and not to assume that you have the condition. Symptoms of RT may mimic other disorders, including some that may be life-threatening if not detected, such as abscesses or malignancy.

In some cases, imaging studies such as x-rays, MRI or CT scans may be necessary for a definitive diagnosis (*Br J Radiol* 2009;82:e117-21).



*Optimal Health University™ is a professional service of PreventiCare Publishing®. The information and recommendations appearing on these pages are appropriate in most instances; but they are not a substitute for consultation with a health care provider. Optimal Health University™ may be photocopied (NOT reprinted) exactly as they are published noncommercially by current subscribers ONLY to share with patients or potential patients. Optimal Health University™ may NOT be reprinted in any print or electronic publication including newsletters, newspapers, magazines or Web sites. Any other reproductions are subject to PreventiCare Publishing® approval. Copyright, 2009, PreventiCare Publishing®. 1-912-897-3040. www.preventicare.com*